

THE MINA.

an FDK Publication





Check out our exchange rates* to bank accounts** in the **PHILIPPINES**

Visit a nearby location.



**Western
Union**

*Western Union also makes money from currency exchange. When choosing a money transmitter, carefully compare both transfer fees and exchange rates. Fees, foreign exchange rates and taxes may vary by brand, channel, and location based on a number of factors. Fees and rates subject to change without notice.

**Services may be unavailable based on certain transaction conditions, including amount sent, destination country, currency availability, regulatory issues, identification requirements. Additional Restrictions may apply. See terms for details.

© 2021 Western Union Holdings, Inc. All rights reserved. All trademarks, service marks, and trade names referenced in this material are the property of their respective owners.

In this Issue:

Messages	4
Meet the Officers	8
Editorial	13
History of FDK	14
FDK Highlights	16
Diode Laser	19
FDK Batch Hinirang	24
FDK Regions	28
Features	31
Directory	39



Arabic: **Mina** مينا /mīnā/

English: **Enamel** /ɪˈnɑm(ə)l/

Hard, outer surface of the tooth; considered the strongest mineral in the human body





Republic of the Philippines
DEPARTMENT OF LABOR AND EMPLOYMENT
Intramuros, Manila



MESSAGE

Congratulations to the great professionals of the Filipino Dentists in KSA (FDK) on your 10th anniversary!

Healthcare workers are vital resources for every country. We all have realized the importance of our health professionals even more now that we are in the middle of a pandemic.

This is why I am so grateful to organizations like the FDK. Despite the uncertainties we are facing, groups like yours are there to provide support to your members, and ensuring that your fellow migrant's rights are protected.

In the midst of a crisis, just the thought that there are people willing to give us support makes a lot of difference. Thus, we cannot overemphasize the significance of the work that you do as an organization.

I would like to thank everyone as well for your valuable contribution to the economy. The personal sacrifice that you make greatly benefits not just your families but our domestic economy, as your remittances are a major driver of local consumption.

With the economic downturn that every nation across the globe has experienced due to the pandemic, your contribution to our economy is more valuable than ever.

I commend your organization for all the good work that you have done despite all the enormous challenges.

I am confident that you will continue to make our country proud with the important work that you provide.

Again, my congratulations on your 10th anniversary. Mabuhay tayong lahat!


SILVESTRE H. BELLO III
Secretary





EMBASSY OF THE REPUBLIC OF THE PHILIPPINES

سفارة جمهورية الفلبين
RIYADH

I extend my warmest greetings and felicitations to the Filipino Dentists in KSA (FDK) as it marks its tenth anniversary as an organization of dentists, dental technicians, dental assistants, and medical representatives here in the Kingdom of Saudi Arabia. I also congratulate FDK on the third issue of its official publication, the *Mina*.

I applaud your initiative in putting together *Mina*, where scientific studies and new trends in dentistry are published and shared amongst your colleagues. Dentistry is a highly specialized field, and so it is essential to be kept abreast of the latest developments and technological advances in your chosen fields. Of equal importance is the need for members to stay updated with the organization's activities. A regular publication like *Mina* is one way to ensure that your members are updated with these trends and developments.

As you move forward into the next ten years, may you continue to espouse the noble values and aspirations of the FDK and inspire those in the dental profession to be dedicated in their craft. May you ever strive for excellence, and always display the best qualities of being a Filipino dental professional with your colleagues and clients. It is your duty as unofficial representatives of the Philippines to show the world that our country has outstanding citizens who can compete with the rest of the world. Rest assured that the Philippine Embassy in Riyadh is always ready to collaborate with FDK and support you as you strive to achieve your goals.

Once again, congratulations! *Mabuhay ang Pilipino saanman sa mundo!*



ADNAN V. ALONTO

Ambassador Extraordinary and Plenipotentiary
of the Republic of the Philippines
to the Kingdom of Saudi Arabia and the Republic of Yemen





Philippine Dental Association

To my fellow Filipinos and Dental Professionals,

Greetings! I hope this message finds you well!

My warmest greetings to all the officers and members of the Filipino Dentists in the Kingdom of Saudi Arabia (FDKSA). Congratulations on your 10th Founding Anniversary of FDKSA!

We are halfway to 2021, and unfortunately, we still continue to experience the challenges of the past year as the pandemic continues to affect our professional and private lives. The advent of vaccines and progressing area-wide vaccination creates hope for normality in the future. It still is a long way to go for all of us, but we have overcome even more critical circumstances in the past. As Filipinos, our resiliency and adaptability reminds us to remain hopeful in all these uncertainties.

This year's PDA's theme, "Fast Forward PDA," is a perfect motivation and inspiration for all dental professionals to remain optimistic and not be halted by the current situation. Let us continue to build and create a new framework for the new future.

My highest regards to your president Dr. Delfin Federico Jr., and his set of officers, for their great legacy in your organization and your community. My support to your new president Dr. Dennis Torres and his group of officers, as they push for more success in their administrative year.

May you continue FDKSA's commitment and reputation in the Philippine Dental Association. I trust that you will maintain your dedication of providing quality oral care to the community and service to your fellow dental professionals by upholding the highest standards of our profession. You indeed are the new heroes of this generation.

Congratulations on your FDKSA's success in achieving its objectives this year.

Fast Forward FDKSA!

Mabuhay and Dentistang Pilipino!

Sincerely,

DR. JOSE ANGELO G. MILITANTE
President
Philippine Dental Association
A.Y. 2021-2022





It's been a decade when a group of professional Dentist gathered and formed FDK – Filipino Dentist in KSA. It was a seed that sprouted into a sturdy oak, and branched to the Central, Eastern, Western, and Northern part of the kingdom. We were molded to exercise our craftsmanship and to extend a noble intention to our Filipino community, not only in the Kingdom, but to our native land as well – the Philippines.

Our theme, "Milestone of Dental Professionalism and Dedication of Service for the Filipino Community," signifies the evolution of FDK to being the competitive and innovative group of professional dentists in the Kingdom. We are favored and admired by our foreign counterpart, not only for our skills, but also for our passion and dedication to our work. Work that we, as OFWs, persevere with patience to provide a better life for our families. Amidst the pandemic, when life is uncertain, when most of our *kababayans* cannot go home, we long to be with our loved ones. Some of us have experienced loss, and although we are overflowed by pain and sorrow, we try our best to gather our strength and foresee a brighter and better tomorrow. FDK Family will always be here to complement and protect each member in harmony. As I say, "We don't leave our men behind."

Commitment is the key to sustain the strength of the organization, the sole element that maintains the flames of our desire to move towards development. On the other hand, loyalty is the back bone that keeps us steadfast. If we combine the two together, there is no doubt that FDK will have a brighter future.

I would like to extend my gratitude to my dynamic Sinagtala team. I look forward to deliver beyond expectations, to adhere to the mission-vision of our CBL, and to commit to the organization. I challenge each member to be proactive and be heard, because your presence is as important as mine. We are stronger in unity. To the good Ambassador H.E. Adnan V. Alonto, rest assured we are here to support you and the government, all the way to the best interest of the Filipino community. To our PDA President Dr. Jose Angelo G. Militante, we work together to deliver and promote Dental professionalism, even across the miles. Lastly, to my wife, Rhenee Rose, as I am blessed to have my second life, thank you for allowing me to be back on track to be of service once again.

Mabuhay ang ika sampung Annibersaryo ng FDK!!!

Mabuhay ang PDA!!!

Mabuhay ang PILIPINAS!!!

Dr. Dennis Jose B. Torres

FDK President, FY 2021-2022



The Executive Committee

Batch Sinagtala



Dr. Dennis Jose B. Torres

Dr. Nicka L. Gaffud

Dr. Maria Leonora S. Reyes

Dr. Jocelyn V. Daquel



Dr. Amelia B. Aldana

Dr. Russel J. Secillano

Dr. Shamira Kristine B. Tonio

THE BOARD OF DIRECTORS



(Top L-R) Dr. Redelma M. Cabal, Dr. Elias B. Fernando, Dr. Imelda B. Marzan, Dr. Delfin R. Federico, Jr.,
Dr. Fe E. Canapi

(Bottom L-R) Dr. Venus R. Kudiylil, Dr. Amalia C. Mingo, Dr. Jill F. Paspé, Dr. Lourdes N. Madayag

The Working Committee



Constitution & Bylaws

Chairman: Dr. Shamira Kristine B. Tonio
Co-Chairman: Dr. Maria Leonora S. Reyes
Member: Dr. Dennis B. Torres



Membership

Chairman: Dr. Lochilene D. Gulmatico
Co-Chairman: Dr. Chona V. Silao
Member: Dr. Merlyn A. Pagulayan



Outreach

Chairman: Mr. Redentor T. Perez
Co-Chairman: Dr. Jocelyn V. Daquel



Food

Chairman: Dr. Aperlita D. Bautista
Co-chairman: Dr. Ma. Theresa C. Torres
Member: Dr. Maria Concepcion A. Papa
Dr. Jill F. Paspe



Program

Chairman: Dr. Nicka L. Gaffud
Co-Chairman: Dr. Yvonne L. Oida
Member: Dr. Shamira Kristine B. Tonio



Awards

Chairman: Dr. Russel J. Secillano
Co-Chairman: Dr. Rhence I. Torres
Member: Dr. Maria Leonora S. Reyes



Sports

Chairman: Dr. Virginia O. Laz
Co-Chairman: Dr. Amelia B. Aldana



Journal

Chairman: Dr. Nicka L. Gaffud
Co-Chairman: Dr. Delfin R. Federico, Jr.



SPLE

Chairman: Dr. Maria Leonora S. Reyes
Co-Chairman: Dr. Joseph C. Horcabas



Continuing Education

Chairman: Dr. Lilibeth L. Gaffud
Co-Chairman: Dr. Elias B. Fernando



Ways & Means

Chairman: Dr. Ariane Danielle A. Lopez
Co-Chairman: Mr. Ace F. Bantay

FDK Eastern Region

VICE-PRESIDENT



Dr. Ethel N. De Leon

SECRETARY



Dr. Natividad R. Marquez

TREASURER



Dr. Ervie M. Muescan

ASST. TREASURER



Dr. Margarita Eva B. Peralta

AUDITOR



Dr. Grace P. Baniyas

P.R.O.



Dr. Gloria O. Paraiso



WORKING COMMITTEE



Dr. Rhona P. Montenegro
Adviser/SPLE



Dr. Amelita A. Hernandez
Adviser



Dr. Arsenia V. Javier
Adviser/Community Outreach



Dr. Shyla E. Roxas
Adviser/Membership



Dr. Malaya T. Manalo
Adviser/Oral Health



Dr. Imelda G. Laurio
Social & Awards



Mr. Greg M. Bassig
Sports



Mr. Rene C. Pia
Ways & Means

FDK Western Region



VICE-PRESIDENT
Dr. Minerva G. Santos



ASST. VICE-PRESIDENT
Dr. Rasmia S. Mapandi



SECRETARY
Dr. Patricia H. Tejada




ASST. SECRETARY
Dr. Raquel Z. Francisco



TREASURER
Dr. Daisy Mae B. Fuertez



ASST. TREASURER
Dr. Maria Perpetua C.
Erazo



P.R.O.
Dr. Robert Angeles D.
Bailon



ASST. P.R.O.
Dr. Diane Claire C.
Tuando



AUDITOR
Dr. Naura S.
Macabanding



**VICE-PRESIDENT
ELECT**
Dr. Julius Adnan S.
Agres

WORKING COMMITTEE



Continuing Education
Chairman: Dr. Flordeliza F.
Bailon
Co-Chairman: Dr. Robert D.
Bailon



SPLE
Chairman: Dr. Patricia H.
Tejada
Co-Chairman: Dr. Raquel Z.
Francisco



Membership
Chairman: Dr. Rasmia S.
Mapandi
Co-Chairman: Dr.
Fatimaadjivir P. Lappang



Outreach
Chairman: Dr. Minerva G.
Santos
Co-chairman: Dr. Kristine
Joy C. Bernardo



Social & Awards
Chairman: Dr. Julius S. Agres
Co-Chairman: Dr. Jennifer R.
Jimenez

COUNCIL OF PAST VPs



Sports
Chairman: Dr. Daisy Mae B.
Fuertez
Co-Chairman: Dr. Jerome C.
Madelo



Constitution & Bylaws
Dr. Jeremiah D. Leung
Dr. Carmencita D.
Malana



Elections
Chairman: Dr. Barbara E.
Padlan



**(L-R) Dr. Jeremiah D. Leung, Dr. Barbara E. Padlan,
Dr. Emely R. Rufino, Dr. Carmencita D. Malana**

FDK Northern Region

VICE-PRESIDENT



Dr. Terence D. Pineda

SECRETARY



Dr. Ma. Resurrecion G. Adan

TREASURER



Dr. Doris A. Holgado

AUDITOR



Dr. Jose J. Lopez

P.R.O.



Dr. Samantha Grace D. Villamin

BUSINESS MANAGER



Dr. Danilo C. Masilungan



WORKING COMMITTEE



Dr. Terence D. Pineda
Food, Ways & Means, Outreach



Dr. Ma. Resurrecion G. Adan & Dr. Doris A. Holgado
Membership



Dr. Jose J. Lopez
Continuing Education



Dr. Samantha Grace D. Villamin
Awards



Dr. Emer O. Estrada & Dr. Josephine P. Perez
Program



Dr. Danilo C. Masilungan
Sports & Outreach

Editorial: Better than Yesterday

They say that when you're down and possibly in the lowest point of your life, that things can only get better. But life is unpredictable and often, things don't go the way we expect them to.

Nobody can deny the difficulty and possibly grief majority of the population experienced or is currently experiencing. Most of them are circumstances directly or indirectly influenced by COVID-19. Since early last year, the pandemic brought drastic changes on a global scale. It spares no race, age, gender, status, or any other category used to differentiate us from each other.

This pushes us to remember a common factor between us all: We are all human beings trying to live this life. Life is mystery and our true role in the grand scheme of things is unknown. Nobody can predict the plot, the climax, or the end of our life stories. There are many things we cannot control or change in this world.

But the thing we **can do** is to strive to be the best versions of ourselves. We should try our best to live every day without regrets. Do the things that make us happy and cherish the people we love.

Another thing this past year forced us to realize is that life is precious, and every day is a gift. Do not feel too guilty to eat the food that you like or reward yourself with material things or experiences that bring you comfort or joy. We should choose to be happy and proactive. We should strive to be more understanding and appreciative. Prefer to move on and move forward. Be good to ourselves and in turn, treat others well.

Life might not get better. It could get worse. But as human beings blessed with a mind to think, comprehend, and create; and a body with strength, skills, and capabilities that have no true limit, we should stop waiting for things to get better. Mark Twain once said that **“The two most important days in your life are the day you are born and the day you find out why.”** We should **choose to do and be better everyday** so that when the day comes and we learn our purpose in this life, we can look back with a smile.

✦ Dr. Nicka L. Gaffud



*Do you want be part of the next issue? Contact us:
filipinodontistksa@yahoo.com*

The Editorial Board

Editor-in-Chief

DR. NICKA L. GAFFUD

Managing Editor

DR. DELFIN R. FEDERICO, JR.

Contributors

DR. ELIAS B. FERNADO

DR. LOURDES N. MADAYAG

DR. RHONA M. SONSONA

DR. TERENCE D. PINEDA

DR. CARMENCITA D. MALANA

DR. LILIBETH L. GAFFUD

DR. RUSSEL J. SECILLANO

DR. YVONNE L. OIDA

DR. SHAMIRA KRISTINE B. TONIO

MS. BEATRIZ ISABELLE I. TORRES

FDK's BEGINNING

Now on our 10th year Anniversary, ten years of challenges, joy, and purpose, I can still recall how it all began. On May 2011, a friend of mine introduced me to a facebook group page of Filipino dentists working in Saudi Arabia, and with the sense of excitement of meeting familiar people, I decided to join. As I saw the page flooded with posts about grievances and complains, I thought about a way to help my colleagues. A message to the admin of the page led to a small group gathering, where I suggested the creation of a group of Filipino dental professionals in the Kingdom. Upon the second meeting, July 22, 2011, Filipino Dentists in KSA (FDK) was born.

At that time, because of the restrictions of the Kingdom, especially for women, we decided and agreed that Dr. Lee Arboleda will be the president and I, the vice president. However, due to the end of his working contract in the country, he was unable to continue his term. Thus, I took over and became the first inducted president of FDK which eventually became recognized by the Philippine Dental Association (PDA) and the Philippine Embassy in KSA. Together with Dr. Lee and rest of the executive committee (EXECOM), we were able to create the organization's logo and formulate FDK's By-Laws which was patterned with the PDA CBL.

After the completion of the requirements, FDK submitted it all to the Philippine Embassy Cultural Affairs for recognition.

The first Induction and Oath Taking of FDK's executive committee, officers, and members took place on October 12, 2011 at the Liwasang Bonifacio, Philippine Embassy, Riyadh. The Certificate of recognition was awarded to FDK, by His Excellency Honorable Ambassador Ezzedin Tago. It was a simple ceremony, yet wholesome and memorable, for FDK is currently the only recognized organization of dentists in K.S.A.

The first grand Induction Ball of FDK was held at the Diamond esteraha on November 2011. We had seminar lectures, raffles, as well as dance and song numbers from our talented FDK officers and members. The first charity project of FDK, "A Toy for Child Joy," was launched. Attendees donated toys and clothes, which were shipped to BANTAY BATA163 in the Philippines. It was sponsored by LBC.

On April 6, 2012, FDK hosted a meeting with the Philippine Professional Organization officers and His Excellency Hon. Ambassador Ezzedin Tago, to which FDK became a non-



2 Linggo, Oktubre 30, 2011 **Baitang Gitnang Silangan** **Pinoy Xtra**

Magkakaibang OFWs sa Jeddah nagbigay ng tulong sa 'distressed' Pinay workers

Binay nakipagpulong sa mga OFWs

Samu't-Sari Patrol

OFW dismayado sa 'remittance'



Apo still member of PPO since we were accomplishing the application for Chartership in PDA. The PPO Induction and Oath Taking was held on June 21, 2012, and the idea of joining the SPLBE, Special Board Exam for Dentistry started.

On October 30, 2011, during the visit of Vice President Binay, a case regarding a fellow dentist in the Kingdom who was detained in her accommodation for a month was repatriated in Philippines a week after FDK's request and involvement.

After the affiliation of FDK in PDA in 2013, the first Online Refresher Program (UP College of Dentistry) was approved by PRC in 2014. On 2015, FDK joined the first SPLBE for dentistry with 8 passers out of 32 examinees. This is one of the biggest achievements of FDK, for non-board passer dentists working in KSA were given a chance to fulfill their dream to become licensed under the Philippine Regulation Commission without going back to Philippines.

All FDK events, programs and activities will not be possible without the help and hard work of the EXECOM, officers, and members. For me, FDK is not only an organization, but a family. The memories that we shared together will be my priceless achievement, and ones that I would treasure from my journey in KSA.

I hope and pray that the next leaders of FDK will continue what we started and aim high for the welfare of the members. May God bless FDK!!! Happy 10th year, anniversary FDK!

◆ **Dr. Lourdes N. Madayag**
FDK's First Inducted President, 2011-2012

function halls
 hotel room
 water park
 gardens
 catering service
 massage spa

BORACANDABA RESORT
 SERVICE with a SMILE

BoraSpa
 REMS Construction & Trading Corporation
 FLYING V

Purok 5 Sta. Lucia (Calinan)
 Sta. Ana, Pampanga

0906 291 8322

Boracandaba Resort

DRM INTERNATIONAL SEA & AIR CARGO

OFW BOX
 Walang Timbangang Bill of Lading at Kilometer Charges

SIZE	M.M	LUZ1	LUZ2	LUZ3	LUZ4	VIS	MIN
Super Jumbo	289	309	329	349	369	389	409
Jumbo	269	289	309	329	349	379	399
Extra Large	219	239	259	279	299	319	339
Large	199	229	239	259	279	289	309
X-Medium	159	169	189	209	229	239	249
Standard	129	139	149	159	179	189	199
Drum Big	259	279	299	329	379	389	399
Drum Medium	189	219	229	249	289	299	329

COMBO PACKAGE
 Walang Hidden Charge at Walang VAT

SIZE	M.M	LUZ1	LUZ2	LUZ3	LUZ4	VIS	MIN
Super Jumbo plus Bultit	299	319	339	359	379	399	419
Jumbo plus Bultit	279	299	319	339	359	379	399
Extra Large plus Bultit	229	249	269	289	309	329	349
Large plus Bultit	209	239	249	269	279	299	319

TV FREIGHT & CREATE RATE ALL IN
 With Insurance

SIZE	M.M	LUZ1	LUZ2	LUZ3	LUZ4	VIS	MIN
19" - 25"	270	280	300	310	320	330	340
26" - 32"	280	290	310	320	330	340	350
33" - 40"	465	475	495	505	515	525	535
41" - 47"	475	485	505	515	525	535	545
48" - 49"	480	490	510	520	530	540	550
50" - 55"	590	600	620	630	640	650	660
56" - 65"	750	770	790	810	830	850	870
66" - 67"	820	840	860	880	900	920	940
68" - 79"	970	1,000	1,030	1,070	1,110	1,170	1,220

WALANG HIDDEN CHARGES

GAS RANGE FREIGHT RATE ALL IN
 With Insurance

SIZE	M.M	LUZ1	LUZ2	LUZ3	LUZ4	VIS	MIN
4 BURNER (TERM) 60X40X92	640	660	680	700	720	740	760
6 BURNER (TERM) 60X65X92	660	680	700	720	740	760	780
6 BURNER (TERM) 65X67X87	690	720	740	770	790	800	810

Contact Person
 Roel Langit Operations Manager
 0504436763

DRM INTERNATIONAL SEA & AIR CARGO

FDK HIGHLIGHTS



2011-2012 Dr. Lourdes N. Madayag

Describes her term: “2011, the formative year of FDK was challenging due to Saudi restrictions. Our concern is always the safety of our members in all our events and activities. (It was) exciting even with our limited fund resources, we were able to accomplish all our projects.”

Her proudest moment: “The oath taking and induction of the FIRST RECOGNIZED ORGANIZATION of Filipino Dentist in KSA.”



2012-2013 Dr. Elias B. Fernando

Describes his term: “2012-2013 Term is the time were FDK completely set the format of organization”

His proudest moment: “The year FDK became affiliate of PDA, APO member of PPO-CRSA, and be recognized by Saudi Dental Society (SDS) as (a) legitimate Filipino Dental Professional Group. The first attempt to have SPLE with 5 examinees and the first publication printed are my team’s proudest accomplishments. We also conducted bowling tournaments, charity works (supported Bantay Bata-beneficiary financial donation) medical and dental mission in Bahay Kalinga”



2013-2014 Dr. Imelda B. Marzan

Describes her term: “Year 2013-2014 the Filipino Dentists in KSA was Soaring Higher especially in spreading their wings through direct involvement in all the Community Outreach Programs under the Philippine Professional Organization (PPO) headed by the Ambassador of the Philippines to Saudi Arabia.”

Her proudest moment: “When FDK was recognized by the Saudi Dental Society in accordance with their respective activities.”





2014-2016 Dr. Redelma M. Cabal

Describes her term: “The success of FDK was further sealed through my own brand of leadership with a theme “Develop...Inspire...Lead”.”

Her proudest moment: “Throughout my two-year tenure, significant programs and projects had been achieved. Most notable was the inclusion of Dentistry in the Special Professional Licensure Board Examination.”

2016-2017 Dr. Jill F. Paspe

Describes her term: “During my term, (it) was full of challenges as well as fun.”

Her proudest moment: “My proudest moment (was) when our SPLE problem was solved by president Duterte.”



2017-2018 Dr. Fe E. Canapi

Describes her term: “6th year of FDK during my term we can’t say there are no challenges and still FDK was a budding organization but with the effortless support of my constituents and BOD, we surpassed any challenges. We made some amendments and resolutions for improvement of FDK.”

Her proudest moment: “I can say the proudest thing during my term which was the creation of a free group study and mock board exam for SPLE Dental exam. We have been doing it during Fridays, sacrificing our free time. Extending our gratifying humanitarian help at the Children Oncology ward of PGH Manila and to less fortunate elders at Tahanan Balik Alay in Rizal as well promoting dental awareness by educating and teaching the proper way of tooth brushing to the children in Philippine Schools in Riyadh.”





2018-2019 Dr. Amalia C. Mingo

Describes her term: “My term was undeniably fruitful, since numerous events and programs were successfully accomplished despite the struggles and financial strain. I am grateful for those who acknowledged that I was able to fulfill all my duties and responsibilities, and even exceeded their expectations.”

Her proudest moment: “My proudest moment was when I represented FDK as the official dental affiliate of PDA in Kingdom of Saudi Arabia, and when our organization received recognitions. I also take pride in knowing I have performed exceptionally, in spite of instances of clamor and retraction of sponsors.”



2019-2020 Dr. Venus R. Kudiylil

Describes her term: “ A member (once) said: there’s a lot of new activities and First(s) in your term; 1st induction held at the Diplomatic Quarters , 1st release of Journal: MINA, 1st Badminton Tournament, 1st Free Photo Booth for oral health promotion, 1st collaboration with the Philippine Embassy: Dental Outreach for Kids, 1st Free Scaling & Tooth Extraction at Meras Dental clinic for distressed OFW(s). And I agreed with her.”

Her proudest moment: “Became the 8th President of FDK and raised a fund amounting to 25,725.78.”



2020-2021 Dr. Delfin R. Federico, Jr.

Term Description: “If I could describe the Hinirang term, I would say challenging. Challenging in a way that it was difficult to plan activities because of the ever changing safety protocols due to the pandemic. It was also a year of realizations, to thrive and be comfortable with the ambiguity of things. Lastly, I believe that our care for each other strengthened, hence FDK Cares.”

Proudest Moment: “I would say, every successful event was already an accomplishment during the term because of the situation. As Dr. Delfin would always say it was difficult but it’s not impossible. The thing that I am most proud of is how the EXECOM and committees worked hard to deliver. The formation of FDK- Northern Region was a product of their passion and dedication to this organization. It was also with these traits that FDK rose up to the challenge.”

** Dr. Shamira Kristine B. Tonio on behalf of Dr. Federico.*



Use of combined wavelength 810 nm + 980 nm diode LASER in multiple soft tissue procedures: Frenectomy, Gingivoplasty, and Gingival Depigmentation

Elias Bergonio Fernando Jr. DMD, PGD, MSc.



Pre-treatment

a) Outline of case

(i) Full clinical description

A 26 years old female patient attended for a routine examination and orthodontic treatment, braces adjustment (Figure 1). She had been a regular patient of the practice during 18 months period and had received examination, hygiene maintenance, and orthodontic treatment to close maxillary and mandibular anterior dental diastemas at monthly intervals as seen in panoramic radiograph (Figure 2) before orthodontic treatment (June 18, 2018). Hitherto, the patient is in the finishing stage of treatment, she expressed a need to evaluate and looking on the possibility of improving her smile aesthetic. She was advised that treatment would involve periodontal plastic surgical procedure. She cannot wait to remove the appliance as the patient is expatriate worker and leaving the country in about 4 months from the date of inquiry.

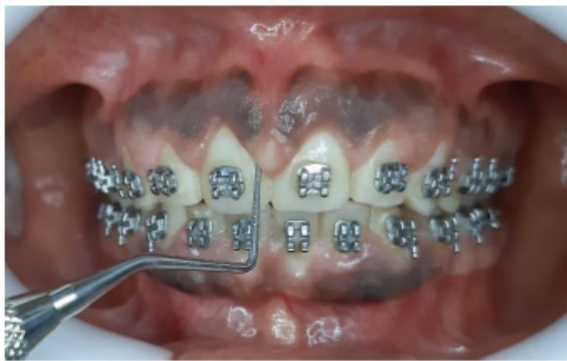

Fig. 1- July 21, 2019 - Intraoral frontal view

(ii) Medical history

The patient is in general good health. No history of hospital admission, no special diet, no allergy to common over the counter drugs, and no food allergy. Common illness like cold, fever, and flu were the reported histories.

(iii) Dental history

Healthy soft and hard dental tissue, no signs of para-oral soft tissue irregularity and no dental cavity noted, no dental filling. All permanent

teeth are present. Normal to the patient the general anterior diastemas present in both arches. However, the patient expressed dissatisfaction with these spaces considering smile aesthetics.



Fig. 2 - June 18, 2018 - Panoramic radiograph before orthodontic treatment.

(iv) Occlusion

After 18 months, re-examination of the dental arches in occlusion and the underlying skeletal landmarks, it was noted that the patient had a Class I molar and canine occlusion (Figure 3), with normal FMP angle and slight curve of spee.

(v) TMJ

Examination of both temporo-mandibular joints, through palpation and radiograph (Figure 4), revealed normal structure and movements. Opening / closing and excursive movements of the mandible revealed no abnormality. No noted problem from the past and during the time of examination.

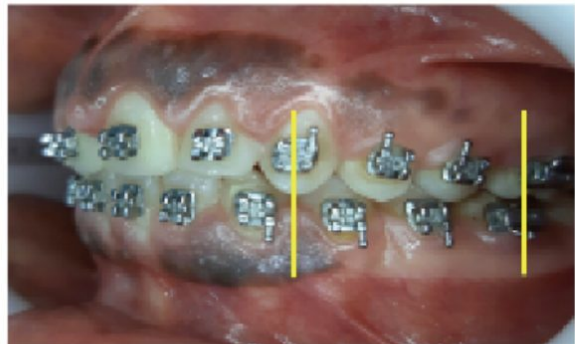


Fig. 3 - July 21, 2019 - Intraoral left later view, angle class I molar and canine relation

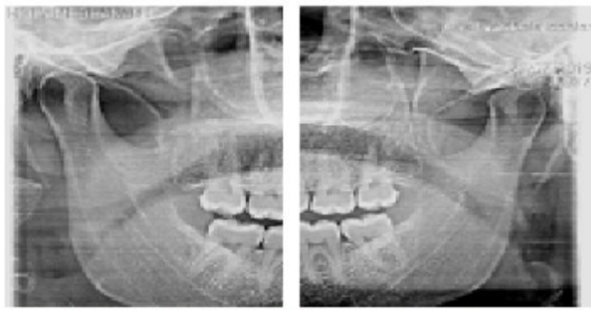


Fig. 4 - June 18, 2018 - TMJ normal condition

(vi) Radiographic exam

On July 21, 2019 panoramic radiograph we're taken to establish both dental and alveolar bone status prior to soft tissue treatment (Figure 5). These views were repeated at stages during the treatment, as required. There was no signs of hard tissue pathology in either jaw and TMJ regions. The alveolar process, alveolar bone proper, and interradicular alveolar bone shows normal. No signs of restoration and no signs of decay or radiolucency on crowns.

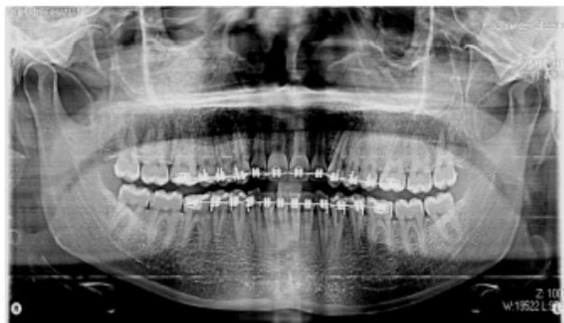

Fig.5 - Panoramic radiograph before laser procedure.

(vii) Soft tissue exam

General oral soft tissue: All soft tissue structures revealed no abnormality and appeared normal in appearance. The dorsal and ventral tongue surfaces, together with tongue movements were within normal expectations.

Gingival soft tissues: All natural tooth sites were examined with a periodontal probe and findings recorded (pre-treatment and re-evaluation). Of specific relevance to treatment provided, there was some false pocketing recorded depths of 3mm at tooth site #6, #7, #8, #9, #10, #11 on mesial and distal aspects of labial and palatal side and on labial of #22, #23, #24, #25, #26, #27 in mesial and distal aspects. Generally, the attached gingivae appeared thickened, yet healthy in appearance. Such slight hypertrophic change may have been due to tissue compression caused about by deliberate orthodontic space closure⁽²⁾ and did not merit any further intervention. The general level of oral hygiene was considered good with no calculus deposits found. Pigmentation of Attached gingiva predominantly on the anterior regions of both arches were noted and appeared normal attributed to patient near dark complexion. Pigmented gingiva is usually seen in dark persons⁽¹⁾.

(viii) Hard tissue status

No signs of dental tissue demineralization.

Tooth vitality test: Normal to hot and cold test.

No complaint.

Mobility: There was no mobility recorded at any natural tooth site.

Percussion: Percussion testing of all tooth sites revealed no hyperaesthesia.

b) Diagnosis

(i) Final diagnosis

Hypertrophic maxillary medial Papilla. Hyperplastic anterior marginal gingival tissues with notable anterior and premolar located hyperpigmented attached gingival tissue.

(ii) Treatment plan outline

I/ general: Gingival tissue recontouring, correction, and enhancement

II/ specific:

[1] Circumferential fiberotomy - conventional pericision of maxillary and mandibular anterior teeth using surgical scalpel blade #11 to reorient and relax the circumferential fibers, this will help to prevent the relapse after teeth consolidation by orthodontic treatment. Pericision would be the first procedure prior to laser use to allow the compressed fibers to be relaxed and assume its new normal unstrained position.

[2] in order to facilitate optimal soft tissue profiles of natural dentition, it was decided to use combined laser wavelength of 810nm + 980nm for maxillary labial frenectomy, removal of hyperplastic gingival tissues associated with teeth #6, #7, #8, #9, #10, #11, #22, #23, #24, #25, #26, and #27. The same laser wavelengths are also prepared to be use in gingival depigmentation of attached gingiva over the root area of teeth #6, #7, #8, #9, #10, #11, #22, #23, #24, #25, #26, #27.

Laser-assisted treatment could be assigned in accordance with the following clinical needs:

i/ maxillary midline frenectomy, this would also aid to prevent dental relapse especially on maxillary midline, relapse after orthodontic treatment⁽³⁾.

ii/ gingivoplasty, to correct the level and contour of free gingival margins⁽⁴⁾.

iii/ gingival depigmentation, to remove thinly dispersed dark pigmentation over attached gingival tissues on labial aspects affecting both jaws.

(iii) Indication and Contraindications

Indications

Treatment: The use of a suitable laser wavelength would seek to meet these requirements. In all areas of soft tissue management within this treatment plan there is an ideal in achieving haemostasis, consistent with the need to provide access and clear

operator surface during and after tissue ablation. In addition, an optimal definition of precision is achievable in terms of selective minimal tissue reduction. A further indication would include the delivery of soft tissue surgery that provides minimal post-operative discomfort and complication for the patient.

Laser: It is recognised that all laser tissue interaction in surgical procedures are predominately photothermal in nature. The conversion of incident laser light energy into heat will lead to primary and, through local conduction, secondary heat effects that would allow soft tissue surgery to be carried out through tissue ablation with a supportive haemostasis. As such, the use of laser energy to effect soft tissue surgery is justified.

Wavelength: The predominant chromophores of the keratinised and non-keratinised gingival tissue in this case are melanin (tissue pigment), haemoglobin and intra-cellular water. In addition, the prime needs of treatment would be to achieve tissue ablation with haemostasis, indicating the optimum need for using a near-infra-red wavelength, such as the 810nm, 980nm, and or by combining the two diode laser wavelengths⁽⁵⁾.

Contraindications

Treatment: The only absolute contra-indication to treatment in this case would be to accept the present situation and condition of the soft tissues. However, in view of the patient's wishes, this was abandoned. Consequently, soft tissue manipulation is mandatory and there can be few if any contra-indications for treatment. In addition, further considerations apply:

a) biologic width (i.e. the sum of the connective tissue attachment, epithelial attachment and sulcular depth relative to the osseous crest) must be determined and considered when re-contouring the periodontium.

b) aesthetic considerations - lip line height, gingival margins relative to the adjacent teeth and of the planned final gingival contour.

Laser: Any surgery using laser energy carries some risk of tissue damage and must be borne in mind.

Wavelength: The choice of a longer wavelength would offer a more superficial level of tissue ablation.

(iv) Precautions

[1] Precision, conventional excision using surgical blade is the elected procedure, this is to precisely incise the supracrestal circumferential periodontal fibers situated below the gingival margins without severing the biologic width.

[2] The benefit of haemostasis offered by near-infra-red laser wavelengths is accepted. In comparison to the Nd:YAG laser, the depth of

penetration of the combined 810nm and 980 Diode wavelength in oral soft tissue is less, which would reduce the risk of collateral thermal damage. Nonetheless, the use of minimum power parameters, time intervals to allow thermal relaxation and control of carbonisation of the tissue and optic fibre, would all reduce the risk of primary and secondary thermal damage.

Maxillary Midline Frenectomy: Tissue traction during laser incision will assist the ability to resect using minimal power parameters. In addition, the laser fibre tip should be angled as near possible, parallel to the alveolar bone, to avoid damage to the hard tissue and periosteum.

Gingivoplasty: Whenever periodontal contouring and tissue removal is undertaken in association with natural teeth, attention must be given to the preservation of the biological width. In addition, preservation of a stable result is dependent on good patient home care.

Gingival Depigmentation: Tissue ablation should proceed slowly and with care to remove any char wherever possible. Also, the laser fibre tip should be angled as near possible, parallel to the alveolar bone to avoid damage to the hard tissue.

(v) Treatment alternatives

Alternative methods for soft tissue incision would include: scalpel, electrosurgery and diamond bur.

(vi) Informed Consent

The treatment plan was fully explained to the patient and all associated risks outlined. A written consent form was signed by the patient in the presence of a witness. The consent form was retained in the treatment notes.

Treatment

(i) Laser operating parameters:

Laser:

The laser used was the Quicklase 12w Dual 810+980nm Diode laser, Made in the UK by Quicklase in Ramsgate-Kent United Kingdom. This laser can use both wavelengths together or individually, 810nm, 980nm or dual 810nm+980nm.

Laser settings:

Maxillary midline frenectomy: 1.5 W (750 mW/810nm + 750 mW/980nm), 400 mm tip diameter, continuous wave in contact/drop mode for 2 minutes. Detailed parameters presented in sheet (Figure 6).

Average power	1.50 watts
% on time	100 %
Peak power	1.50 watts
Tip area	0.0013 cm ²
Spot diameter at tissue	0.0400 cm
Spot area at tissue	0.0013 cm ²
Peak power density	1194 w/cm ²
Average power density	1194 w/cm ²
Total energy	180.0 joules
Energy density with movement	187.3 j/cm ²

Fig. 6 - Frenectomy laser parameters

Gingivoplasty: 1 W (500 mW/810nm + 500 mW/980nm), 400 mm tip diameter, continuous wave in contact/brushing mode for about 20 minutes on all subject teeth. Detailed parameters presented in sheet (Figure 7).

Average power	1.00	watts
% on time	100	%
Peak power	1.00	watts
Tip area	0.0013	cm ²
Spot diameter at tissue	0.0400	cm
Spot area at tissue	0.0013	cm ²
Peak power density	796	w/cm ²
Average power density	796	w/cm ²
Total energy	1200.0	joules
Energy density with movement	125.0	j/cm ²

Fig. 7 - Gingivoplasty laser parameters

Gingival Depigmentation: 1 W (500 mW/810nm + 500mW/980nm), 400 mm tip diameter, continuous wave in light contact/swiping mode for about 15 minutes on both arches. Detailed parameters presented in sheet (Figure 8).

Average power	1.00	watts
% on time	100	%
Peak power	1.00	watts
Tip area	0.0013	cm ²
Spot diameter at tissue	0.0400	cm
Spot area at tissue	0.0013	cm ²
Peak power density	796	w/cm ²
Average power density	796	w/cm ²
Total energy	900.0	joules
Energy density with movement	125.0	j/cm ²

Fig. 8 - Gingival depigmentation laser parameter

(ii) Treatment delivery sequence:

Preliminary to patient treatment:

- Secure operating room, define controlled area and place proper laser warning signs
- Set up laser and test for proper laser operation.
- Test fire laser, employing all safety measures, using minimum power settings and direct beam onto articulating paper. Objective is to ensure correct laser operation, patency of delivery system and emission of cutting and aiming beams. In addition, the fibre tip can be inspected to ensure a proper cleave has been carried out and the spot size is uniform.
- Supplies dispensed, equipment and sterile instruments arranged
- Patients information: review charting, x-rays, and sequence of planned procedure
- Patients seated: review treatment plan and informed consent
- Safety: eye protection placed, patient first followed by operating personnel.

Treatment sequence:

Individual treatment sites were isolated and infiltration local anaesthetic administered (2% Medicaine 1/100,000 Adrenaline with 1/100,000 epinephrine).

Pericision: The incision of circumferential fibers on all anterior teeth was carried out with the use of #11 surgical blade. The blade is oriented apically and passed through gingival sulcus up to alveolar crest, cuts are made interproximally on each side of tooth in facial and lingual surface.

Maxillary midline frenectomy: The optic fibre was freshly cleaved and lightly initiated following the setting guidelines (Figure 9. 8 x carbon contact with 300 mW). Laser power setting set to 1.5 Watts and CW. The labial tissue was placed under tension to identify the profile of the muscle fibre insertion. Holding the fibre perpendicular to the tissue surface and parallel to the alveolus at 2-3 mm away from fixed gingival tissue, an initial incision was performed. With the tissue under tension, the incision was developed to a depth where superficial muscle fibres were parted and no blanching or movement of gingival tissue observed. Care was taken to avoid char build-up in the tissue or on the fibre tip and the incision restricted to achieve the surgical objective.



Fig. 9- a - Laser initiation settings and beam profile. b - carbon paper initiation

Gingivoplasty: Check retractor is used at this time to firmly hold the lips and away from the subject tissue. Laser power setting was reduced to 1 Watts with CW. From the maxillary left quadrant to right then continue to mandibular right to left quadrant the ablation was achieved. All middle gingival margins (facial) are preserved and used as guiding plane, the laser fiber is oriented apically parallel to the alveolus and gentle sweeps the bulbous gingival tissue ensuring tip and tissue light contact. Any char on the tissue or fibre tip was removed with damp gauze. Successive sweeps of the fibre allowed precise tissue cleavage to be carried out, to a point where final excess tissue removal could be achieved with a sharp curette. In this way, direct contact with the underlying tooth was avoided. A minor degree of difficulty in carrying out ablation was experienced in the palatal side, the orientation of the tip is limited to a slight angulation and most of the time ends-up ablating perpendicular to the tooth, extra caution was applied by changing the technique to drop-off and momentary ablation.

Gingival depigmentation: Laser power setting: 1.0 Watts CW. With the fibre freshly cleaved

and initiated. 1-3 mm/sec. tip movement/swiping motion in cervical-apical direction overlying keratinised gingiva. The procedure lasted 15 minutes. Ablation is directed only to all hyper-pigmented tissues with slight lateral extension of about 1 mm until the observance of reddened tissue surface but not too deep reaching the blood vessels. Extreme caution was exercised not to overheat the underlying bone by frequently wetting the tissue.

(iv) Post-operative instruction

The surgical sites were shown to the patient and their appearance explained (Figure 10). Normal oral hygiene is advice and avoid the disturbance of the coagulum; this should be carried out during the five-day post-operative period. The patient was informed that the appearance of the treatment sites would change, with detachment of the coagulum at fixed gingival sites and softening and hydration of loose tissue at the frenectomy site at 3-5 days post-operation. The patient would be reviewed at one week. Post-operative analgesia was prescribed for use as required. Avoid spicy and highly acidic food but there were considered no limitations on eating or drinking. The patient was instructed to call if any problem should occur and was called by phone after 24 hours.

(v) Complications

Complications that can be expected following laser soft tissue surgery can include pain, tissue swelling and deformation, bleeding and infection. In this case, no such complications were encountered.

(vi) Prognosis

Laser-assisted soft tissue procedures, employing correct power parameters generally have a very good prognosis. It was felt that in this case a similar outcome could be expected

(vii) Treatment records

All procedural details, both generally and specifically with reference to the laser use, were entered in the patient's treatment notes, along with the consent details, radiographs and chartings. As such, the treatment records would reflect the treatment outlined above.

Follow up

(i) Assessment of treatment

The patient was reviewed at one week, with successive treatment sessions thereafter at monthly intervals. The soft tissue sites were therefore regularly reviewed initially and at 3 months, and plan to assess at six months and one year. The frenectomy, gingivoplasty, and depigmentation procedures resolved rapidly during the initial two week period (Figure 12). In all cases, the healing was as expected and normal oral function was maintained.

(ii) Complications

No long term complications were observed.

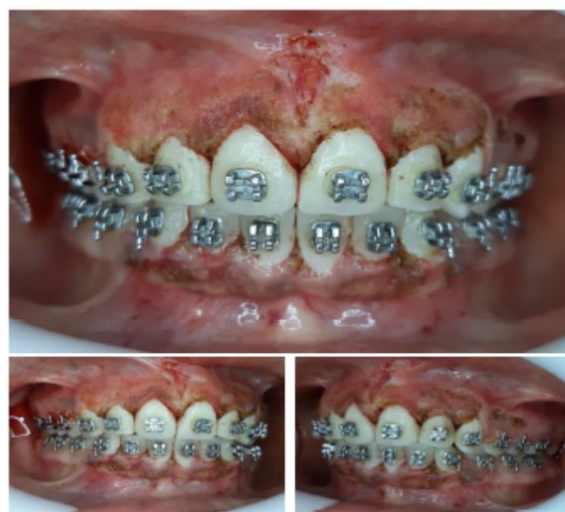

Fig. 10 - After laser procedure (frenectomy, gingivoplasty, and depigmentation) intraoral frontal view

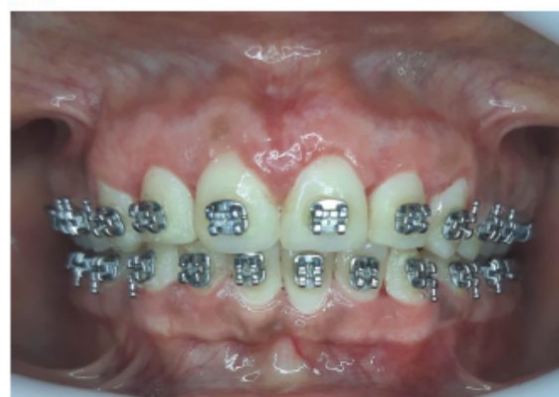

Fig. 11 - August 4, 2019. Post-operative tissue condition (after 2 weeks)

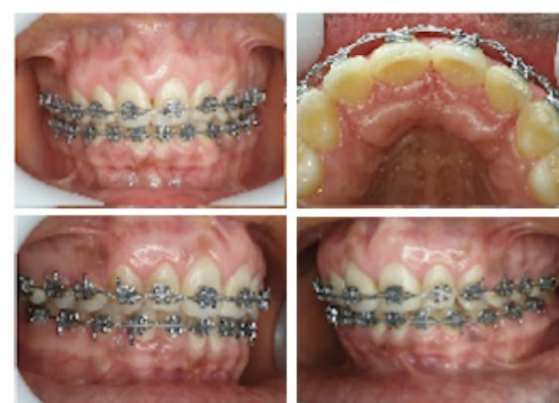

Fig. 12 - Nov. 23, 2019 - After 4 months

REFERENCES:

1. Oluwole D, Elizabeth D. Gingival tissue color related with facial skin and acrylic resin denture base color in a Nigerian population. African Journal of Biomedical Research. 2010;13:107-111.
2. Rafiuddin S, Yg PK, Biswas S, Prabhu SS, Bm C, Mp R. Iatrogenic Damage to the Periodontium Caused by Orthodontic Treatment Procedures: An Overview. Open Dent J. 2015;9:228-234.
3. Devishree, Gujjari SK, Shubhashini PV. Frenectomy: A review with the reports of surgical techniques. JCDR. 2012;6:1587-92.
4. Shankar S, T R, S NM, Reddy S, Saritha G, Reddy M. Chronic inflammatory gingival overgrowths: laser gingivectomy & gingivoplasty. J Int Oral Health. 2013;5(1):83-87.
5. Mojahedi S, Bakhshi M, Babaei S, Mehdipour A, Asayesh H. Effect of 810 nm diode laser on physiologic gingival pigmentation. Laser Ther. 2018;27(2):99-104.

THE CHOSEN ONES

When the pandemic unexpectedly hit the world hard last year, there was much fear, confusion, and distress. Watching how COVID-19 affected the world, our colleagues, friends, and family- it would not be surprising to be discouraged and fall into a routine of unproductive days. The pessimists were convinced that the end of the world was near, while the more optimistic individuals treated it as a waiting game; waiting for the virus to disappear and for everything to return to normal. But while many patiently waited, there was an equal amount of the population who allowed fear to reign. Anxiety ensued, resulting in families hiding away in their homes. They abandoned social, familial, work, and other obligations, even self-improvement was on a standstill. FDK batch Hinirang with the leadership of Dr. Delfin R. Federico, Jr. did none of those things. Instead, the officers took advantage of the situation, testing the limits and possibilities and overcoming them despite all the challenges.

Some of the notable accomplishments from this administrative year are:

- ✳️ Launch of the Hinirang Lecture Series: Webinar Edition:
 - “Potpourri of Removal & Fixed Appliances in Orthodontics” with Dr. Federico Nadela, Jr.
 - “Orthodontics & Esthetic Dentistry: The Next Level” with Dr. Geraldin A. Cruz
 - “Veneer Cementation Protocol” with Dr. Haitham Tawfeek Youssef
 - “Prosthodontic Treatment Modalities of Damaged and Missing Teeth: Then and Now” with Dr. Jose J. Lopez
 - “Endodontic Regeneration” with Dr. Ahmed Madfa
 - “Impacted Teeth & Failures in Their Removal” with Dr. Lucia S. Valderrama
- ✳️ Affixed and further developed the member emergency and medical assistance fund:
 - FDK Cares: Financial support is given to members who:
 - Tested positive to COVID-19
 - Were admitted to the hospital for any medical problem
 - Lost immediate family members
 - Need legal assistance
 - Lingap Kababayan: Support and assistance given to fellow Overseas Filipino Workers (OFWs) in form of food, daily necessities, oral hygiene kits, or free medical and dental services
 - Lingap Kabataan: Support given to the OFWs’ school children through dental hygiene kits, dental education, or dental services
- ✳️ 2 Successful Clean up Drives:
 - Hidden Canyon Clean-up drive: where members covered 75,000 Sq. meters, collecting 23 large bags of trash with a total weight of 137 kilograms
 - Coastal Clean-up Drive: Organized in partnership with FDK- Eastern region with the participation of 103 volunteers from other organizations (GBI-ACPPI, ACCPI/ OFW AFCSCOM/OFW, PSME, IMFIAK, MGII, PINASAHI, FILPOP, CSI, CONGRESS, IBCWA, IIEE, PROFILBAA, LP/IBCWA, LP/DESERT, PNA/ERSA). Approximately 309 kilograms of trash was collected.
- ✳️ First Induction Ceremony linked with the Philippine Dental Association via Zoom platform. PDA President- Dr. Alvin M. Laxamana, EVP- Dr. Cheryl Y. Del Rosario, Dr. Noel O. Leynes , and Chief protocol officer- Dr. Reynaldo D. Agcanas actively took part in the program.
- ✳️ Successful Activities in-line with PDA:

- HISO Campaign: where posters were put up in several Filipino establishments in Riyadh (Fiestahan Restaurant Al Jazeera Mall, Sherbetes Bistro Al Jazeera Mall, Pinoy Supermarket Al Batha, Pasalubong Restaurant Al Batha, Pasalubong Restaurant Sulimaniyah).
 - National Toothbrushing Day Selfie & Groupie competition participation
 - “Ako ay Dentista, Front-liner Din” Campaign active participation.
 - National Dental Health Month Celebration where dental hygiene kits were distributed in Sulaimania District, Batha, and Jadeed Senaya
- ✦ Formation of FDK Northern Region

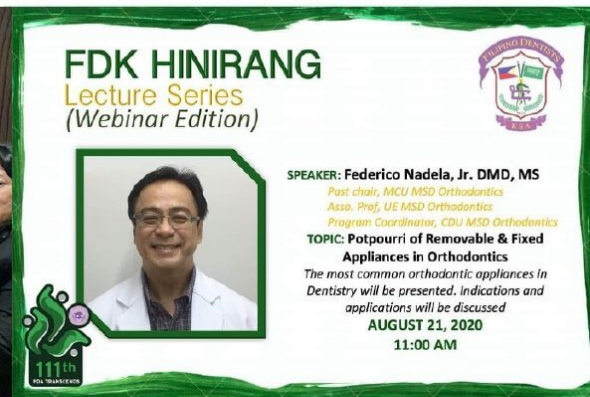
It can be said that this batch of officers was aptly named ‘Hinirang’- the chosen ones. If FDK can accomplish as much when so many limitations were set, imagine the possibilities when the world has finally recovered from this pandemic. It is without a doubt a source of pride to be part of such a dynamic team of dental professionals who don’t hold back from sharing their skills, time, and resources. Cheers to FDK and more fruitful years to come!

✦ **Dr. Nicka L. Gaffud**
FDK HINIRANG SECRETARY

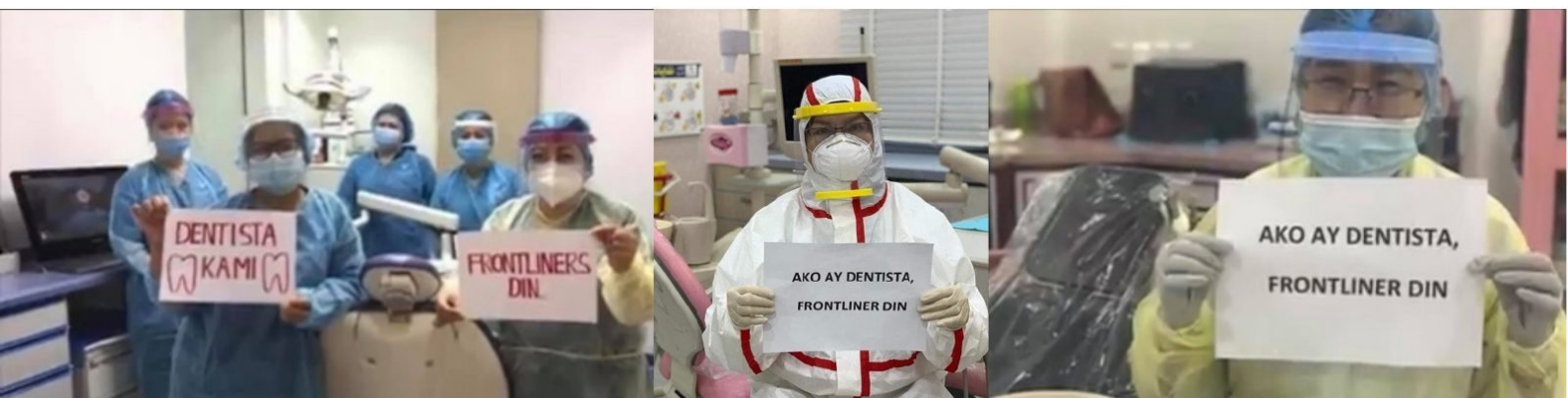“One can choose to go back towards safety or forward towards growth. Growth must be chosen again and again; fear must be overcome again and again.” -Abraham Maslow



First Meeting & Photoshoot of Batch Hinirang Officers
August 14, 2020
Mariott Hotel, Diplomatic Quarters



1st Lecture Series
August 21, 2020
Zoom



“Ako Ay Dentista, Frontliner Din” Campaign
August 24, 2020

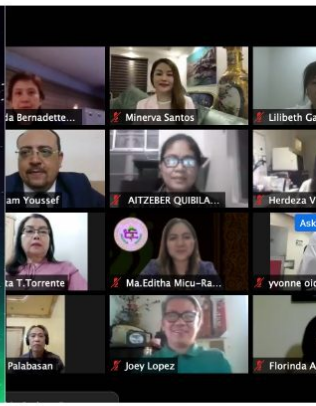FDK HINIRANG Lecture Series
THE WEBINAR EDITION
presents
ORTHODONTICS & ESTHETIC DENTISTRY
THE NEXT LEVEL
< from smile analysis to diagnosis & treatment planning >

with **Geraldin Abesamis-Cruz, DMD, MSD**
President, Philippine Academy of Esthetic Dentistry
Associate Member, Association of Philippine Orthodontists

SEPTEMBER 18, 2020
02:00PM Riyadh Time /
07:00PM Philippine Time

See you at: **PDA ZOOM PLATFORM**

2nd Lecture Series
September 18, 2020
Zoom



FDK HINIRANG Lecture Series
Webinar Edition

VENEER CEMENTATION PROTOCOL

Dental Veneers are one of the best solutions that you can give to your patients to change their life prospective, career and self-confidence. Focus will be on different Veneers types, Cementation options and procedure, tooth and veneer treatment and clinical cases.

DR. HAITHAM TAWFEEK YOUSSEF,
BDS, MSC. 3M SCIENTIFIC AFFAIRS AND EDUCATION

OCTOBER 23, 2020
3PM (RIYADH TIME)

3rd Lecture Series
October 23, 2020
Zoom



Trip to the Edge of the World
November 20, 2020



HISO Campaign
November 20-21, 2020



9th Induction Ceremony
December 4, 2020
Holiday Inn Meydan Hotel



Clean-up Drive
January 15, 2021
Hidden Canyon Riyadh



4TH FDK LECTURE SERIES: WEBINAR EDITION
JANUARY 22, 2020
2PM (KSA TIME)
7PM (PHILIPPINE TIME)

Prosthetic Treatment Modalities of Damaged and Missing Teeth: Then and Now
Jose Nazareno Lopez, DMD, MA, MS
Lecturer & Course Director: Prosthodontics
Restorative Dental Science Department
University of Ha'il

Endodontic Regeneration
Ahmed A. Madfa, BDS, MSc, PhD
Associate Professor: Endodontics
Restorative Dental Science Department
University of Ha'il

4th Lecture Series
January 22, 2021
Zoom



Coastal Clean-up with FDK-ER
 January 29, 2021
 Half-moon Beach, Al Khobar



5TH FDK HINIRANG LECTURE SERIES: WEBINAR EDITION
 FEBRUARY 19, 2021
 1PM (KSA TIME)
 6PM (PHILIPPINE TIME)

TOPIC: IMPACTED TEETH & FAILURES IN THEIR REMOVAL

EVALUATION, CLASSIFICATION, ASSESSMENT, APPROPRIATE TREATMENT, MANAGEMENT, PROPER DIAGNOSIS AND COMPLICATIONS IN THE SURGICAL INTERVENTION OF EMBEDDED AND ABNORMALLY POSITIONED IMPACTED TEETH WILL BE DISCUSSED



DR. LUCIA SARMIENTO VALDERRAMA
 PROGRAM TRAINING DIRECTOR / CONSULTANT, POSTGRADUATE COURSE IN HOSPITAL DENTISTRY METROPOLITAN MEDICAL CENTER

5th Lecture Series
 February 29, 2021
 Zoom



NDHM Celebration
 February 26, 2021

First FDK-NR Meeting
 March 13, 2021



Last Meeting of Committees with the BOD
 April 2, 2021
 Holiday Inn Meydan



GA & Formation of FDK-NR
 April 10, 2021



Labor Day Celebration: Medical/Dental Mission
 May 1, 2021
 Philippine Embassy, Riyadh, KSA
 27

FDK-WR TRANSCENDS



It was six months into the pandemic when I took office on June 2020 as Vice President of the FDK-Western Region. The world seemed so bleak with everyone on high alert as the focus was on the increasing number of casualties of the COVID-19 virus. It was during those troubling times that the first FDK Executive Committee meeting was held and 'batch Hinirang' was established to go through the seemingly impossible feat of flourishing amidst the pandemic.

Despite the problems arising from the strict health protocols and restrictions set by the government, we were able to plan and accomplish most of our programs and activities. We held our regular meetings via video conferencing platforms and this constant communication brought us closer, lifting our spirits with hope.

One of the timeliest programs was FDK Cares, where active members in need received financial and legal assistance. Members who tested positive to the virus also received financial support from FDK central. We tried our best to cut back on expenses and gave leeway to our members who had difficulty in settling the membership dues. We believe that moral support is important during these times when many were negatively affected by the pandemic and experienced much loss.

On August 28, 2020, in line with 'Lingap Kabayan', an FDK outreach program, we distributed 220 bottles of shampoo and liquid soap to the distressed Filipinos inside the Philippine Consulate grounds. On Christmas morning, we delivered food and gifts to 20 Filipino workers in HUTA Company who did not receive their salary for 8 months.

In line with the National Dental Health month in February 2021, 'Lingap Kabataan' was done by conducting Dental Health Education online for 3 Filipino International Schools in Jeddah: Al Durah International School, Durat Al Shark International School, and International Philippine School in Jeddah. On February 23 and 24, 2021, 215 grade 5 and 6 students benefited from a lecture on Oral hygiene and Dental diseases. On February 25 we also collaborated with the Philippine Professional Organization in giving a Career Orientation talk to Senior High school students, promoting Dentistry as a rewarding career.

We were able to pursue Continuing Education for our members by actively participating in the FDK Lecture Series which was held almost every month. Everyone enjoyed and learned much from being part of the organizing committee and working with veteran speakers/lecturers from the Philippines and in the Kingdom. Everyone was also up to date on several local and International Dental webinars available throughout the year.

Despite the cancellation of the SPLE for Dentists and Dental Technologists, the online review group page was set up and updated to encourage them to continue studying and practicing for the exam.

A very memorable and successful 4th FDK-WR Turn-over and Induction ceremony was held in Al Rawdah Hotel Jeddah on December 11, 2020. Graced with the presence of our supportive colleagues from FDK Central in Riyadh, PCG dignitaries, sponsors, families, and friends.

Our Family Day was held in Reem Riviera Beach Resort on January 8, 2021. Sharing of food and having fun during our team building activities made us realize that being together strengthens the bond between us all.

I can only look back now and say that sometimes the best thing you can do is not worry, nor wonder, not imagine, nor obsess. Just breathe and have Faith that everything will work out for the best.

✦ **Dr. Carmencita D. Malana**
FDK-WR Hinirang Vice-President

THE FORMATION OF FDK-NORTHERN REGION

The Filipino Dentists in the Kingdom of Saudi Arabia Northern Region (FDK-NR) began with the vision of one man from Riyadh in the person of Dr. Delfin Federico, Jr. who happened to be the organization's president for the administrative year of 2020-2021. It all started when Dr. Delfin had a conversation with Dr. Jose J. Lopez, the committee chairman of continuing education at that time. He referred Dr. Terence D. Pineda as the contact person to facilitate the creation of the FDK-NR. On March 12, 2021, at Sam rah Park, several professionals in the field of dentistry (dentists and dental technicians) with diverse backgrounds gathered for one common objective. The collaboration led to the appointment of Dr. Terence as chairman, who was assigned to spearhead the first batch of members from the northern region until an official election could be held. He acted as the officer-in-charge before the formal ceremony. Thereafter, dates for the general assembly, election, and the induction of the new sets of officers were calendared.

On the faithful day of April 9, 2021, the realization has come with the official formation of FDK-Northern Region. It was culminated with the presence of the FDK President Dr. Delfin, Past FDK President Dr. Amalia C. Mingo, and other officers and members of the organization. Dr. Terence D. Pineda was officially elected as its first Vice president with Dr. Ma. Resurrection G. Adan as the Secretary, Dr. Doris A. Holgado as Treasurer, Dr. Jose J. Lopez as Auditor, and Dr. Samantha Grace D. Villamin as P.R.O. All the newly elected officers took an oath of office, thereafter, officially becoming part of the list of officers of the Filipino Dentists in the Kingdom of Saudi Arabia, which is an affiliate of the mother organization- Philippine Dental Association in the Philippines.

The FDK-NR is committed to following the guiding principles parallel to the PDA and FDK advocacies and endeavor to perform all the duties and responsibilities in accordance with the Constitution and Bylaws. FDK-NR looks forward to forming alliances with other groups and entities to promote goodwill and build camaraderie among our fellow dental health professionals; initiate social services to address oral health concerns of the community; boost morale and exercise the highest form of professionalism in the northern part of the Kingdom of Saudi Arabia.



❖ **Dr. Terence D. Pineda**
FDK-NR Sinagtala Vice-President

RETHINKING ROOTS

The Filipino Dentists in the Kingdom of Saudi Arabia (FDK) established its foundation as a legitimate Filipino community organization with its first induction on October 12, 2011, spearheaded by the first inducted FDK President Dr. Lourdes N. Madayag with Ambassador Ezzedin H. Tago in the Philippine Embassy, Riyadh. FDK commenced the induction of its officers and members in 2012, unifying the dental professionals and gearing towards excellence. On May 9, 2014, FDK-Eastern Region (FDK-ER) was recognized as an official member of the Philippine Professional Organizations in Saudi Arabia (PPO-SA) with the assistance of Dr. Jeffrey Singson and the Labor Attache of the Philippine Overseas Labor Office-Eastern Region Operations (POLO-ERO), Atty. Alejandro A. Padaen. They carried out their first dental mission in the Eastern Region; curated by the Safwa Association of Filipino Expatriates (SAFE) with the aid of the nurses from Ram Dental Care and medical staff in Mohammad Dossary Hospital under the supervision of Ms. Mary Jane Tupaz. The accreditation of chartership was granted to FDK-ER by FDK under the presidency of Dr. Redelma Macapili-Cabal in the administrative year of 2014-2016. Civic actions were initiated, including medical-dental missions during the Filipino Community Day and MMG Camp. The consistent efforts of Dr. Rhona Montenegro-Sonsona reaped the fruits of her labor when she was elected as the Vice President of the FDK-ER in December 2014. This enabled her to undertake the privilege of serving the Overseas Filipino Workers (OFWs) while simultaneously developing both her professional and personal facets. After a year of incumbency, the FDK-ER affiliation became an organization member of the All Filipino Community and Sports Commission (AFCSCOM). FDK extended its influence on the youth by conducting consecutive programs vis-à-vis oral health awareness and dental health checks in the three (3) Philippine schools of the Eastern Region in February 2016. In celebration of the Philippine Dental Association's (PDA) National Dental Health Month, FDK-ER commemorated its first Dental Health Month through a month-long line up of activities dedicated to students at all school levels. Activities included dental lectures with companies employing OFWs and outreach programs in the

Eastern Region. These events granted FDK-ER a position as an organization member in the OFW-Congress on March 18, 2016. FDK has been growing steadily throughout the years and has managed to serve its purpose in supporting advocacies for dental health professionals in the Kingdom while providing superb services to their patients and the community.

❖ Dr. Rhona M. Sonsona
❖ Ms. Arianne Rañeses



JRLT TRADING
EXCLUSIVE DISTRIBUTOR OF ORTHODONTIC AND DENTAL PRODUCTS

+639209221946
(02)416-5339

f JRLT TRADING ORTHODENTAL

myobrace®
STRAIGHT-TEETH THE NATURAL WAY


myosa® 3M DENTAL PRODUCTS

MRC

POWARGARD®
MOUTH GUARDS

A meaningful life

is not being rich, being popular, being highly educated, or being perfect. It's about being real, being humble, being able to share ourselves and touch the lives of others.



Inspiring Quotes
FAILURE IS NOT THE OPPOSITE OF SUCCESS. IT IS PART OF SUCCESS.

GRATITUDE

DEVELOP AN "ATTITUDE OF GRATITUDE".
SAY THANK YOU TO EVERYONE YOU MEET FOR EVERYTHING THEY DO FOR YOU.

EVERYTHING HAPPENS FOR A REASON

(AMERICAN PRAYERS)

WORDS TO INSPIRE US

"It is our attitude at the beginning of a difficult task which, more than anything else, will affect its successful outcome."

WILLIAM JAMES

Our family has been blessed with an eternal love and enormous happiness. God is so kind that He gave me a husband whose devotion sets no limit, children who respect and adore their parents and a career that has fulfilled my dreams and expectations.

Thus on that day when my husband died before my eyes in just a matter of minutes, I became the saddest woman on earth. Only then did I realize that the saying "Life is short! "is really true.

You will ask me how I remained strong and was able to endure this ordeal of losing your loved one who has been my constant companion for 37 long years. My answer: it is my faith in the Almighty, support of my daughters and friends that keep me going and the belief that "There is a Light at the End of the Tunnel"

Yes, Words have the power to motivate and energize us. Reading quotes resembles eating a piece of Patchi chocolate or a slice of a delicious Dulce de Leche cake.

It can open our minds to see life in a wider perspective. Quotes often open the eyes and the mind to understand truths and acknowledge things you otherwise would have missed. It is like drinking a cup of "Starbucks coffee" that suddenly uplifts your spirit.

And if you are on the verge of giving up or struggling to push yourself to the next level, they can change your state of mind in a minute. By creating a positive environment you can train your brain for success and embrace life's ups and downs.

I have collected these sayings in an effort to boost your mental wellbeing and to kick those blues away. I believe that one day I will meet my Creator and I will see my crush (Husband) again ...

❖ **Dr. Lilibeth L. Gaffud**

"When I was diagnosed with Breast Cancer that day and my husband handed me a magazine with George Clooney on the cover, my room suddenly changed from Gray to Bubble Gum Pink!" -*Dr. Lilibeth Lim Gaffud Best Letter of the Month- Sayidaty Magazine distributed in the Middle East, North America and Europe.*

.....
Life IS NOT ABOUT WAITING FOR THE STORM TO PASS BUT LEARNING TO DANCE IN THE RAIN
.....

Happiness is an inside job

Be with someone who is good for your mental health.

Unknown




WHATEVER LIFE GIVES YOU, EVEN IF IT HURTS JUST BE STRONG AND ACT LIKE YOU'RE OKAY STRONG WALLS SHAKE BUT NEVER COLLAPSE.



IT'S YOUR TURN TO SPEAK

Speaking is one of the main forms of communication. More often than not, we were caught on the crossroads on when to speak or not to speak. Are you one of those who wants to crawl under the table during the graded recitations in the classroom? Or one who hides behind the lectern or podium when asked to speak in a company event? Or the one who just hides their face in order to not be recognized when asked to say something in a family gathering?



It is nothing to be ashamed about, we were all once at that same phase; but choosing to stay in that state is what is truly shameful. As we all know, life is a continuous process of learning and conquering our fears is something that should be a goal. Learning to collect and organize our thoughts then expressing our opinions through speaking can take us to different places.

It is inevitable for us to encounter a situation wherein we really need to speak. Students are often being called in a graded recitations and presentations of projects in school. There will come a time where we may be called upon to speak in our family and friends' gatherings and occasions. Part of the job of company executives and leaders of organizations is to conduct, facilitate, and preside in meetings. Speaking should not be feared as we do it every single day; speaking to our friends, colleagues, fellow members and employees. These are only some of those situations.



Here are some tips I have learned through the years that you could find helpful and interesting on your road to becoming a better speaker.

- 1. Listen** – this is what I believe to be the most important element of speaking. Before we speak, we must learn how to listen. In this way, we will learn to get involved in the conversation on point. We will also know how and when to respond if being asked and be able to share our own opinion of the subject matter relevantly.
- 2. Read, Read, and Read** – One of the responsibilities of being a good speaker is to have a wide range of references from books, newspapers, magazines and the internet. Nowadays, with just a click of the finger we can have all the related information on what we need to know. Having stock knowledge will definitely help a lot.
- 3. Know Your Audience** – When being asked to speak, it is important to know who will be attending or listening to your speech or presentation. We want our audience to be engaged and involved in our presentation so giving relevant and relatable examples is a must.

4. **Know Your Audience** – When being asked to speak, it is important to know who will be attending or listening to your speech or presentation. We want our audience to be engaged and involved in our presentation, so giving relevant and relatable examples is a must.
5. **Prepare the Beginning and Ending** – When being asked to make a speech, these two parts of our speeches are the most important. The beginning gets the attention of our audience and sets the mood of the entire message we want to convey. On the other hand, the ending or conclusion is the part where in we generalize the entire content of our speeches and our take home message to our audience.
6. **Use Body Language** – Hand gestures, smiling, frowning, looking at your audience from left to right are some of the examples. Non-verbal form of communication adds impact, color and texture to your speech, use it wisely and purposely.
7. **Control Your Fear** – Not everyone is gifted to be a good speaker. I do believe that the good speakers are made and not born. Knowing to control your fear and channeling this same fear into a more productive one differentiates a pro from a neophyte speaker. It won't happen overnight but I am sure it will get better the more times you do it.
8. **Arrive early at the Venue** – It is better to arrive ahead of the others during your speaking engagements. In that way, you can check the hall, auditorium, or gymnasium where you will speak. You can do a sound-check and try out the height of the lectern/podium if it is suited to your height. It is better to greet the audience as they arrive (not unless you're a surprise speaker) because it is better to speak to an of audience that you get acquainted with than with total strangers.



Benefits of Speaking:

1. **Personal** – We learn to be more sensitive and skilled as a speaker as we continue to deliver speeches. It encourages us to look into our own personal experiences and share it with others; we normally use these as examples in our speeches. Personal stories make us more human to our audience. We also learn to consider our listener's needs, wants, and likes.
2. **Practical** – Honing our speaking skills can give and get us anywhere and everywhere. Good oral communications is one of the top skills demanded by employers when we are applying for most jobs. We learn to be more confident, speaking concisely and clearly. It helps us to speak out in important situations as a parent, citizen, or customer. We can also learn the ability to persuade others more efficiently.
3. **Cultural** – We learn to avoid stereotypes and widen our understanding on things that happen around us.

Every time we are given the opportunity to speak, let us embrace that opportunity to share something to the world. Learning to be an effective speaker is never too late; we just need to have a teachable mind and heart.

POSITIVE THINKING

The human mind is the most complex thing in the universe. It could bring harmony and happiness and consequently improve almost all aspects in our life. A positive outlook makes better relationships and drives us to succeed in any endeavor we choose. The way we think matters and influences how we can adopt to the difficult and challenging stages in our lives.

Positive Thinking is a Strength

Positive thinking is an attitude which is mental in nature. If you believe that anything is possible through mental determination, you will eventually feel well and healthy. In result, your confidence boosts allowing you to be persistent to overcome any impediments and succeed in the end.

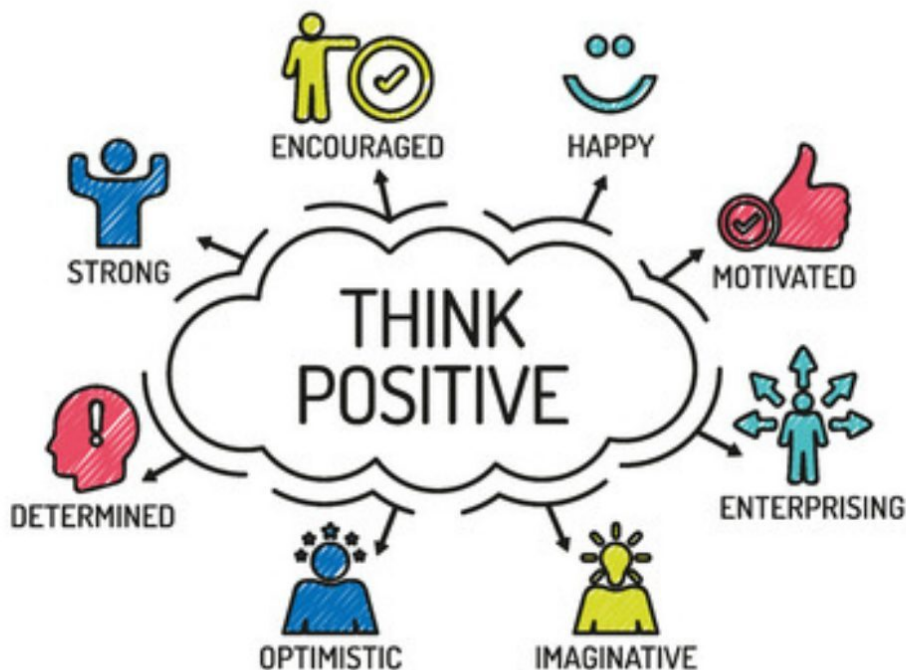What Is Positive Thinking and Why You Need It?

Positive thinking is the mental and emotional attitude of expecting good and favorable results, even when plans do not proceed as expected. It means trying to overcome setbacks and achieve the goal without getting discouraged.

Positive Attitude will lead you to Success

Did you know that one of the most important keys to success is a positive attitude? With a positive state of mind, it is easier to achieve success, improve relationships, have better health, achieve happiness, inner peace, and satisfaction. It makes it easier to avoid worries and negative thoughts. Adopting a positive attitude as a way of life will allow you to cope with whatever life throws your way.

“THE PEOPLE WHO SUCCEED AREN’T THE ONES WHO AVOID FAILURE; THEY’RE THE ONES WHO LEARN HOW RESPOND TO FAILURE WITH OPTIMISM” - Darrin Donnelly



YUMMY CHICKEN ASADO

By Dr. Terence D. Pineda

Ingredients:

- 500 grams chicken (we used legs, thighs, and wings)
- 4 pieces calamansi
- 3 tablespoons soy sauce
- 2 tablespoons canola oil
- 1 tablespoon butter
- 2 tablespoons white onion, chopped
- 1 1/2 tablespoons garlic, chopped
- 1 piece laurel leaf
- 2 1/2 cups tomatoes, chopped
- 1 tablespoon soy sauce
- 2 teaspoons brown sugar and salt, to taste
- 1 1/2 tablespoons atsucte oil (annatto oil)



Cooking Technique:

1. Marinate chicken pieces in calamansi juice and soy sauce. Chill in the fridge for about 4 hours.
2. Heat oil and butter in a pot over medium high heat.
3. Sear the chicken pieces for 4-5 minutes per side or until lightly golden brown. Remove the chicken from the pan and set aside.
4. In the same pan, sauté onions, garlic, bay leaf and tomatoes. Allow to simmer for 3-4 minutes then add soy sauce and brown sugar and mix well.
5. Return the chicken back to the pan and simmer further for 15-30 minutes or until chicken is cooked.
6. Add atsucte oil and seasonings to improve and savor the taste.

NO BAKE TRIPLE CAKE

By Dr. Russel J. Secillano

Ingredients:

- 1 pack Caramel
- 400ml fresh milk
- 1 can fruit cocktail
- 1 pack Gelatin
- 1/2 bar of melted butter (unsalted)
- 3/4 cup sugar
- 1 small can heavy cream
- 3 cups of any powdered milk



Cooking Technique:

1st Layer

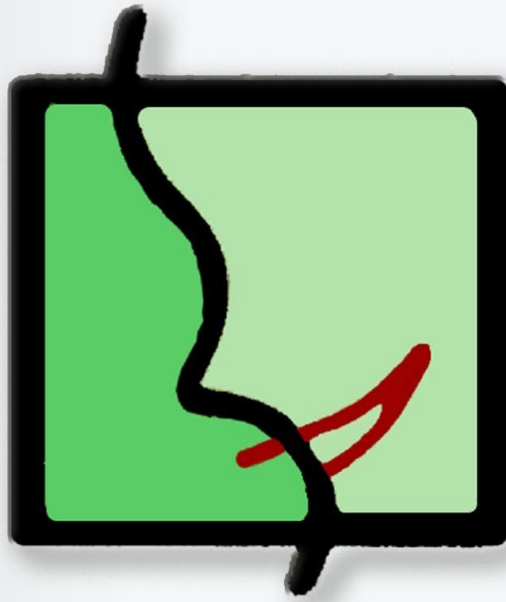
- In a pan mix caramel powder and fresh milk. Bring to a boil. Set aside.
- Pour on the desired platter of your choice, (round or square) Refrigerate.
- Drain well the fruit cocktail and put on top of the caramel.

2nd Layer

- Dissolve 1 pack of gelatin in 2 and 1/2 cup of water. Bring to a boil and then set aside.
- Pour gelatin slowly on top of the fruit cocktail
- Refrigerate until set.

3rd Layer

- In a bowl, mix milk powder and heavy cream. Add sugar and the melted butter
- Mix thoroughly until the mixture thickens, spread evenly on top of gelatin mixture until smooth
- Refrigerate for 2-3 hours
- Invert the cake, serve chilled
- Garnish with mix fruits and mix nuts (optional)



Smile DENTAL CLINIC



205 6060



055 221 8888



www.smile.sa



DR. BADAR AL SHAMMARI,
BDS, MS, FRCD(C)

COMBO BUNDLE



10 GB

500
Minutes
All Networks

2 +
GB

FREE

70 SAR

Price including
15% VAT 80.50

Dial *112# to activate
30 Days Validity



FRIENDI package provided by Virgin Mobile Saudi Consortium LLC.



DentaCube

3M

Orthodontics

3M Official Distributor

5th floor Northridge Plaza Mall
#12 Congressional Ave. Quezon City
Contact no: 09178989391/09175961972
8426-7840

FDKSA 2021-2022

To: Bro.Dr.Pres.Dennis,

I am sending my warmest congratulations on your victory as President of FDKSA 2021-2022, with the Theme: A Milestone of Dental Professionalism and Dedication of Service for the Filipino Community. You are a hard to find person who puts their whole heart into everything that they do. Your association is lucky to have you, so dedicated with unwavering commitment to the 3 Cardinal Principles of Alpha Phi Omega, to be a Leader, to be a Friend and always ready to be of Service!

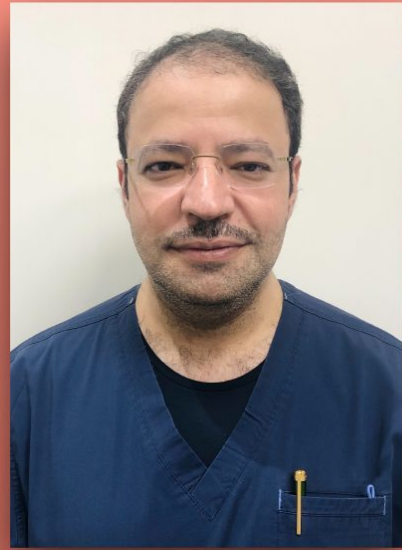Congratulations on your achievement. Keep it up!
You make your APODAP Family Proud!
May We Always Be and God Bless You!

Liezl Ceballos, DMD, MSc.
APODAP
Past President 2003-04

President/CEO
DentaCube Inc.
5th flr. Northridge Plaza Mall
#12 Congressional Ave. QC
09178989391/09175961972
02-84267840
dentacube@gmail.com
dentacubeinc@gmail.com



*Congratulations Dr. Dennis Jose B. Torres
from Mr. & Mrs. Mario M. Vera Cruz*



Abdulaziz Soud Al-Rasheed, B.D.S., M.S.,
 -Diplomate of the American Board of Periodontology
 -Professor in Periodontics at King Saud University, Riyadh, Saudi Arabia
 -Consultant Periodontist at Coral Co. for Med. Serv.

“You need to empower people. You need to encourage people. That’s what builds a great team.”



Congratulations

Dr. Dennis Jose B. Torres

From Mr. & Mrs. Oliver B. Cayetano

Member Directory: Central

ADORABLE,NOVA
0535016406
ALDANA,AMELIA B.
King Abdulaziz Medical City, Naseem
0508737841
ALVIEDO,CEDRALINE R.
Rasheed complex Medical city
AlFursan St.Okaz district
0552301138
AMORIO,MERCEDES B.
Coral Dental clinic
West Mohammadiyah Imam Saud KSA
0537113715
AMOYO,MA.CONCEPCIONE.
ARASULA,NORA V.
Sigal Dental clinic
0509439326
AYA-AY, MA.TEHRESA D.
Al Ewan Medical Polyclinic
Abi Masaud Al Badri St. Sulaimania
0500949541/0114631606
BANTAY,ACEF.
Medical supply & Ministry of Health
Warehouse Sakaka city Al Jouf province
0507017291
BAUTISTA,APERLITA D.
Qasr Al Sewak Poly dental clinic
Exit 26 Hamza bin Muttalib st Badia
Riyadh
0114317559
CANAPI,ELONA B.
Al Razi Polyclinic
0114824370
COMETA,ZORAIDA D.
Riyadh Care Hospital
0504306765
CRUZ,GLORIA B.
Al Sham dental & dermaSC
Ibn Tatmiah st. Al Shifa
0508019020/0112980008
DACQUEL,JOCELYN V.
Sigal Dental clinic, Thalateen St.
0553917313
DANNANG RITA C.
Safa al Oroba Medical complex
King Abdulaziz rd Hawtat Sudair 15333
0507884426/0555929411
DE LEON,ARLENE A.
Bait al eilaj dental clinic
Ibn Taymiah st Shifa Riyadh KSA
0509784530/011222240
DINGRAT,MAYLOVILLA *
Prince Sultan Military Medical city
0534503562
DORIA,FILIPINAS D. *
Coral Dental clinic
Imam Saud Bin Abdulaziz rd
0538064251
EDADES,IRENEN. *
Specialized Medical Center
0550928549
ESPARAGO,LOLITA M.
Almuhaidib Malak Alkharj
0507822353
ESTRADA,EMERLITA O.
Safa Al Oroba Medical Complex, Al Hayyit
0581381360
FEDERICO,DELFIN JR.
Al Mawiyah Consultative clinic #6,
0544871271/0114615599
FERNANDO,ELIAS
Nova Dental group
0563169297
GAFFUD,NICKAL.

Meras Clinics Suweidi
Western Ring Road Al Badiah exit 28
0597670906/0114311188
GAFFUD,LILIBETH L.
Riyadh Elm University
2931177 ext 177
GALLANO,LIZA
GIRONELLA,TERESITA
Al Sukacyber ,Medical complex, Al Kharj
0552911974
GUIAL,ARLENE
Prince Sultan Military Medical city
0509613088
GUICO,ROSEMAYS. *
Prince Sultan Military Medical City
0565689366
GULMATICO,LOCHILENE D.
Olaya Polyclinic complex, Thalateen St.
0530626810
HORCABAS,JOSEPH
Riyadh Care Hospital
0507046512
JALALI,NURHANINA B.
Ivan dental clinic
Laban suburb neighborhood Prince
Ahmed Bin Abdulaziz st
0534854691
KUDIYIL,VENUS R.
Meras Clinics Suweidi
Al Badiah, Exit 28
0114311188/0114328187
LAZ,VIRGINIA O.
Al Hannuf Medical clinic
Al Rawdah 3 Electricity st
0501276403/0112262203
LOPEZ,ARIANE DANIELLE A.
Tip Al Safwa
East Naseem
0559878773
LOPEZ,JOSE NAZARENO J.
University of Hail
0559987869
LUMAQUE,CECILIA C
LOYOLA,MILDREDS. *
King Faisal Specialist hospital
0544743976
MADAYAG,LOURDES N.
FAC dental center
Khalid Bin Walid st Riyadh
0568132380/0112304242
MALUBAY,RONALYN M.
MAMON,LORETTA A.
NGHA King Abdulaziz medical city
DAKashmalan KSA
0553868412
MAMA,LATIP*
MALA,DIRONI. *
MALUBAY,Ronalyn M. *
Specialized Medical center
MARZAN,IMELDA B.
Al Muhaidib dental center
Abi Al Aswad Naseem Riyadh
0509174247
MENDOZA,RAQUEL
Smile Way Medical complex
0112286614
MINGO,AMALIA C.
Al Nozha Medical center
Othman Bin Affan rd Riyadh
0509011684/920009899 loc5240
MUHI,MA.THERESA *
Prince Sultan Military Medical city
0571840295
OIDA,YVONNE L.

Al muhaidib dental group
Tarmoudi st Al shifa area
0502180541
OMORONG,HAYDEEM. *
Specialized Medical Center
0532597155
PABLICO,RACQUEL *
Prince Sultan Military Medical city
0554836701
PAGULAYAN,MERLYN *
Image Dental clinic
Takasushi rd Riyadh
0507897318/0114836060 ext 105
PAPA,MA.CONCEPCION
Durrat Al Alami dental clinic
0535066635
PASPE,JILL FRENCH
Al Faiha Medical clinic
Al Imam Ahmed Bin Hannibal st
0550071592/0112328888ext706
0542911898
PEREZ,REDENTOR *
Nassaim Al Khozama dental lab
Mamfhoza Riyadh KSA
0507038924
PURIFICACION,MITOSM.
Meras Dental center, Shifa
0114222171
REYES,MA.LEONORA *
Prince Sultan Military Medical city
0508235940
RIVERA,JANINE M. *
Prince Sultan Military Medical city
0532357728
RODRIGUEZ,RUZETTE M.
Adwaa Al Eilaj Medical complex
0114963962
SECILLANO,RUSSEL J.
Coral dental clinic
West Mohammadiyah Imam Saud
0506987459
SILAO,CHONA V.
Al Alami Medical, Badiah
0562671066
SOLAR,SHEILA *
SUERO,DELCE AMOR *
0507317318
TANAEL, IRENE
0541433986
TIONGSON,CRISTINA G. *
King Saud University
0532682172
TONIO,SHAMIRA KRISTINE B.
Nakheel Medical center
Sulay Al Saadah area exit 16
TORRENTE,VIOLETA T.
Safwa Muhaidib Abha st
Fahad rd,Bisha City
0546039337
TORRES,DENNIS
Al Alami Medical clinic
Khalid Bin Waleed st King Faisal
0543526511/0112482991 loc 231
TORRES,RHENESE ROSE L.
King Faisal Specialist hospital
& Research center
0552284180
TORRES,MA.THERESA C.
Adwaa Al Alami, Olaya Al Nakheel
0114702211d
TUMLOS,SHANE *
VILLASOR MAE *
Sigal dental clinic
0567944591

Member Directory: Regions

EASTERN REGION:

Bahjin, Rosalyn Shia
Kayan Medical Complex
0551933314

Banias, Grace
Armed Forces Hospital
0502100913

Bassig, Greg Dt
Armed Forces Hospital
0537336808

Briones, Esther
Sweet Medical Clinic
0508216026

Caliwag, Carmina Castro
Armed Forces Hospital
0532594432

Cardoza, Sheryl B.

Cerbito, Dorothy Grace
Armed Forces Hospital
0567981620

De Leon, Ethel N.
Hagar Medical Clinic
0564784852

Fortuna, Ervic Muescan
Nova Dental Complex
0551884752

Gabriel, Ma. Novelites G.
Dr. Khaled Al Ateeq Dental Clinic
0568868403

Hernandez, Amelita Alejandro
Al Rhidah Polyclinic
0567014918

Javier, Arsenia V.
Ram Dental Care Main Branch
0509336196

Jiao, Edilberto E.
Armed Forces Hospital

Laurio, Imelda Gloriano
Danna Dental Center
0537357177

Manuel, Jermelina F.
Al Atebaa Dental Center
058403727

Marquez, Natividad Rivera

Nurbidre, Sitti Nambra O.
Armed Forces Hospital

Orchengco, Irene Cabrera
0556172038

Peralta, Margarita Eva B.
Advanced Medical Clinic
0506347880

Pia, Carlo G. Dt
Al Maghlouth Polyclinic
0534832758

Pia, Eric Dt
Al Maghlouth Polyclinic
0534832758

Pia, Rene G. Dt
Al Maghlouth Polyclinic
0534832758

Robles, Amorelle G.
Armed Forces Hospital
0556581344

Roxas, Shyla A.
Ytoog General Medical Complex
0537589870

Sonsona, Rhona Montenegro
Jabal Ram Dental Center
0555698018

Tanael, Irene Alis
Dependent
0541433986

Tangpos Elsa D.

Dr. Khalid Al Ateeq Dental Clinic
0554251674

Tiongco, Josephine A.
Armed Forces Hospital
05804033727

Valenciano, Bien Rachel S.
King Fahad Hospital University
0507231374

Yutangco, Agnes A.
Yatoog General Medical Complex
0507873755

WESTERN REGION:

Aquino, Sheila Marie G.
0531815812
Arm Forces Military Hospital
Khamis Mushayt

Abante, Merriann E.
0533454962
Andalusia Dental Center
Makarona St. Jeddah

Agres, Julius S.
0551949467
King Abdulaziz University Col of Dent
Al Jameah District, Jeddah

Bailon, Flordeliza F.
0561613247
Jeddah International School
Alrawdah Dist, Jeddah

Bailon, Robert Angeles D.
0560222175
Shar Dental Center
Madina Road, Rawdah Dist. Jeddah

Bautista, Margie Quirimit
0530257078
Arm Forces HSR
Khamis Mushayt, KSA

Beloria, Elza Jean
0545880603
Andalusia Dental Center
Makarona St. Jeddah

Cruz, Mikko Jed A.
0599125670
Bassam Specialist Medical and Dental
Al Salamah District, Jeddah KSA

De Leon, Jovy B.
0552783928
Retal Dental Center
Al Gazzaz Center, Al Hamraa District Jed

Erazo, Maria Perpetua C.
509953305
King Faisal Specialist Hospital
Khaladiya Dist. Jeddah

Francisco, Raquel Z.
0509225542
First Future Medical Complex
Al Sanabel, Jeddah

Jadoon, Judie
0533263723
Andalusia Dental Center
Makarona St. Jeddah

Jimenez, Jennifer R.
0551300336
Riyada Dental Clinic
7410- Al Khuzama Dist Bisha

Labe, Adelaiden G.
0531232716
King Abdullah Medical Center
Al Makkah

Lappang, Fatimaadjivir
057 328 8740
Retal Dental Clinic
Al-hamra gazaz centre, cornich

Leung, Jeremiah D.
0551788734
Shar Dental Center

Al Rawdah Dist. Jeddah

Magpili, Rhealyn
0537320198
National Guard Health Affairs –
WR, BHARA

Malana, Carmencita D.
0567568459
Shar Dental Center
Rawdah Dist, Jeddah

Mapandi, Rasmia S
+966544276900
Shar Dental Center
Al Rawdah Dist. Jeddah

Medina, Charmaine A.
0580349982
Andalusia Dental Center
Makarounah St, Jeddah

Minoza, Lennie E.
0559733847
Dr. Munir Harasani Dental Clinics
Al Murjanah Tower Prince Sultan, Al khayal, Jeddah

Montemayor, Tiffany P.
554577687
Harasani Dental Clinics
Prince sultan st. Jeddah

Olaco, Alien S.
0552631976
Dr. Ibrahim Masoud specialty dental clinic
Jamjoom Palestine St., Jeddah

Ortua, Rhodora Ubando
0551873638
Arm Forces Military Hospital
Khamis Mushayt

Palomo, Aileen M.
05544661748
Retal Dental Clinic
Al-hamra gazaz centre, cornich

Pascua, Christopher
055 264 0460
Al Manar Specialized Medical Center
Al Manar District Jeddah KSA

Ramos, Lyra Sharon F.
0501400521
King Abdulaziz Medical City
P.O. BOX : 9515 JEDDAH 21423

Rivera, Patty Flor G.
0538500759
Ideal Clinic
Thalia, Jeddah

Rufino, Emely R.
0554528075
King Abdulaziz University Col of Dent
Al Jameah District, Jeddah

Ruppe, Jazmin S.
505665751
Andalusia Dental Center
Makarounah St, Jeddah

Santos, Minerva G.
0535574436
Medical Reference center
King Abdulaziz Rd, Al Naddah Dist, Jeddah

Taguim, Leah
050 005 4476
Eyadati For Dental
Ahmad Al Attas, Al Zahra Dist Jeddah

Tuando, Diane Claire C.
0542849741
Retal clinic for cosmetic and implant dentistry
Al hamraa Gazzaz center

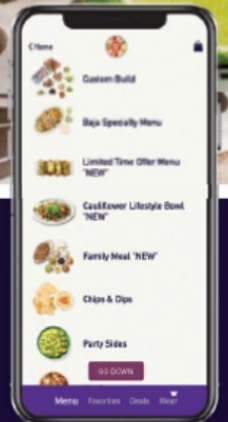Tejada, Patricia H.
05011164608
Ideal Clinics,
Al Manar Bldg, Thalia St., Jeddah

Valenzuela, Elizabeth
565648234
Dr. Adnan Gholam Medical Complex



BURGER MEXICANA

Your favorite cheeseburger, Mexican style,
is now in Fire&Grill!



FIREGRILL
FRESH MEX KITCHEN



فایر جریل
فریش میکس کیتچن

Download on the
App Store

GET IT ON
Google Play

No receiver charges¹ in the Philippines with Western Union.

When receiving money at over 21,000 agent locations² and channels, including:

Cash pickup:



Direct to bank accounts:



Pull to a mobile wallet³:



WesternUnion \\ WU

¹ Applicable taxes may be charged in some locations.

² Network data valid as of June 30, 2021

³ Funds will be paid into a receiver's mobile wallet account provider for credit to account tied to receiver's mobile number. Additional third-party charges may apply, including SMS and account over-limit and cash-out fees. Funds availability subject to terms and conditions of the service. See Mobile form for Restrictions.

© 2021 Western Union Holdings, Inc. All rights reserved. All logos, trademarks, service marks, and trade names referenced in this material are the property of their respective owners.

**Send money in minutes*
for cash pick-up or to
mobile wallets** in the**



PHILIPPINES

Visit a nearby
location.



**Western
Union**

*Funds may be delayed or services unavailable based on certain transaction conditions, including amount sent, destination country, currency availability, regulatory issues, identification requirements, Agent location hours, differences in time zones, or selection of delayed options. Additional Restrictions may apply. See terms for details.

**Funds will be paid to receiver's mWallet account provider for credit to account tied to receiver's mobile number. Additional third-party charges may apply for use of funds e.g. cash-out. Funds availability subject to mWallet provider's Terms and Conditions.

© 2021 Western Union Holdings, Inc. All rights reserved. All trademarks, service marks, and trade names referenced in this material are the property of their respective owners.



DR.WILD Dental

Made in Switzerland



MASTIHA ART OF NATURE

Made in Greece

